

5-2011

## Safety of Cervical Manipulation: Are Adverse Events Preventable and Are Manipulations Being Performed Appropriately?

Joseph Anders  
*University of Nevada, Las Vegas*

Jessica March  
*University of Nevada, Las Vegas*

Amber Perez  
*University of Nevada, Las Vegas*

Follow this and additional works at: <https://digitalscholarship.unlv.edu/thesesdissertations>



Part of the [Alternative and Complementary Medicine Commons](#), and the [Physical Therapy Commons](#)

---

### Repository Citation

Anders, Joseph; March, Jessica; and Perez, Amber, "Safety of Cervical Manipulation: Are Adverse Events Preventable and Are Manipulations Being Performed Appropriately?" (2011). *UNLV Theses, Dissertations, Professional Papers, and Capstones*. 1303.

<http://dx.doi.org/10.34917/3004137>

This Thesis is protected by copyright and/or related rights. It has been brought to you by Digital Scholarship@UNLV with permission from the rights-holder(s). You are free to use this Thesis in any way that is permitted by the copyright and related rights legislation that applies to your use. For other uses you need to obtain permission from the rights-holder(s) directly, unless additional rights are indicated by a Creative Commons license in the record and/or on the work itself.

This Thesis has been accepted for inclusion in UNLV Theses, Dissertations, Professional Papers, and Capstones by an authorized administrator of Digital Scholarship@UNLV. For more information, please contact [digitalscholarship@unlv.edu](mailto:digitalscholarship@unlv.edu).

SAFETY OF CERVICAL MANIPULATION: ARE ADVERSE EVENTS  
PREVENTABLE AND ARE MANIPULATIONS BEING  
PERFORMED APPROPRIATELY?

By

Joseph Anders

Bachelor of Science, Kinesiology  
University of Nevada-Las Vegas  
2007

A research article submitted in partial fulfillment of  
the requirements for the

**Doctor of Physical Therapy  
Department of Physical Therapy  
School of Allied Health Sciences  
Division of Health Sciences**

**Graduate College  
University of Nevada, Las Vegas  
May 2011**

SAFETY OF CERVICAL MANIPULATION: ARE ADVERSE EVENTS  
PREVENTABLE AND ARE MANIPULATIONS BEING  
PERFORMED APPROPRIATELY?

By

Jessica March

Bachelor of Science, Health Ecology  
University of Nevada-Reno  
2008

A research article submitted in partial fulfillment of  
the requirements for the

**Doctor of Physical Therapy  
Department of Physical Therapy  
School of Allied Health Sciences  
Division of Health Sciences**

**Graduate College  
University of Nevada, Las Vegas  
May 2011**

SAFETY OF CERVICAL MANIPULATION: ARE ADVERSE EVENTS  
PREVENTABLE AND ARE MANIPULATIONS BEING  
PERFORMED APPROPRIATELY?

By

Amber Perez

Bachelor of Science, Kinesiology  
University of Nevada-Las Vegas  
2008

A research article submitted in partial fulfillment of  
the requirements for the

**Doctor of Physical Therapy  
Department of Physical Therapy  
School of Allied Health Sciences  
Division of Health Sciences**

**Graduate College  
University of Nevada, Las Vegas  
May 2011**

Copyright by Jessica March 2011  
All Rights Reserved

Copyright by Amber Perez 2011  
All Rights Reserved



THE GRADUATE COLLEGE

Date

This Doctor of Physical Therapy Research Project prepared by

**Joseph Anders**

entitled

**Safety of Cervical Manipulation: Are Adverse Events Preventable and Are Manipulations Being Performed Appropriately?**

Is approved in partial fulfillment of the requirements for the degree of

**Doctor of Physical Therapy**

Merrill Landers, Research Project Coordinator, Department of Physical Therapy

Harvey Wallman, Chair, Department of Physical Therapy

Ronald Smith, Ph. D., Vice President for Research and Graduate Studies  
and Dean of the Graduate College

**May 2011**



THE GRADUATE COLLEGE

Date

This Doctor of Physical Therapy Research Project prepared by

**Jessica March**

entitled

**Safety of Cervical Manipulation: Are Adverse Events Preventable and Are Manipulations Being Performed Appropriately?**

Is approved in partial fulfillment of the requirements for the degree of

**Doctor of Physical Therapy**

Merrill Landers, Research Project Coordinator, Department of Physical Therapy

Harvey Wallman, Chair, Department of Physical Therapy

Ronald Smith, Ph. D., Vice President for Research and Graduate Studies  
and Dean of the Graduate College

**May 2011**





THE GRADUATE COLLEGE

Date

This Doctor of Physical Therapy Research Project prepared by

**Amber Perez**

entitled

**Safety of Cervical Manipulation: Are Adverse Events Preventable and Are Manipulations Being Performed Appropriately?**

Is approved in partial fulfillment of the requirements for the degree of

**Doctor of Physical Therapy**

Merrill Landers, Research Project Coordinator, Department of Physical Therapy

Harvey Wallman, Chair, Department of Physical Therapy

Ronald Smith, Ph. D., Vice President for Research and Graduate Studies  
and Dean of the Graduate College

**May 2011**

## ABSTRACT

### **Safety of Cervical Manipulation: Are Adverse Events Preventable and Are Manipulations Being Performed Appropriately?**

by

Amber Perez  
Jessica March  
Joe Anders

Dr. Louie Puentedura, PT, DPT, GDMT, OCS, FAAOMPT  
Research Advisor  
University of Nevada-Las Vegas

Dr. Merrill Landers, DPT, OCS  
Research Project Coordinator  
University of Nevada-Las Vegas

**Objectives:** Documented case reports found in medical literature describing adverse events associated with cervical spine manipulation (CSM) were reviewed to determine if the CSM was used appropriately and if the events could have been prevented. Our hypothesis was that CSM had been used inappropriately and that adverse events could have been prevented. This study also looked to identify potential characteristics that may put the patient at risk for injury, or even death as a result of a CSM. **Methods:** One hundred and thirty four cases, reported in 93 articles, published between 1950 and 2010, were reviewed. CSMs were categorized as 'appropriate' or 'inappropriate', and adverse events associated with the CSM were categorized as 'preventable', 'unpreventable' or 'unknown'. **Results:** Chi square analysis showed no significant difference in proportions between appropriateness and preventability,  $p=.459$ . Of the 134 cases, 60 (44.8%) were categorized as preventable, 14 (10.4%) were unpreventable and 60 (44.8%) were categorized as 'unknown'. CSM was performed appropriately in 80.6% of cases. Death

resulted in 5.2% (n=7) of the cases, mostly caused by arterial dissection. **Discussion:** There is no association between appropriateness of cervical manipulation and preventability of adverse events. If all contraindications and red flags have been ruled out, there is potential for a clinician to prevent 44.8% of adverse events. Additionally, 10.4% of the events were unpreventable, suggesting there may be some inherent risk associated with CSM even after a thorough exam and proper clinical reasoning.

## Introduction

Cervical spine manipulation (CSM) is utilized by physical therapists, chiropractors, and other healthcare practitioners to treat a multitude of disorders, most commonly headaches, neck pain and stiffness.<sup>1</sup> For the purposes of this study, CSM is defined as a passive manual therapy intervention utilizing high velocity low amplitude movement that cannot be prevented by the patient.<sup>2-4</sup> The safety of CSM has been an issue of significant debate since 1907, when the first adverse event was reported.<sup>5</sup> Much of the debate regarding the safety of CSM may be attributed to the lack of agreement between incidence reports of serious adverse events following CSM, which vary between 1 per 50,000 to 1 per several million.<sup>6,7</sup>

While there is little agreement between incidence figures, it is evident that there is some risk associated with CSM. Several literatures reviews have suggested that the risks associated with CSM outweigh the benefits.<sup>1,2,8,9</sup> This conclusion was made due to the lack of evidence supporting any benefits of CSM to offset the risks associated with the technique.<sup>2</sup> Additionally, after retrospective review of cases involving cerebrovascular accident (CVA) following CSM, Haldeman et al (2002) concluded the risks associated with CSM are inherent and the occurrence of serious complications appears to be unpredictable.<sup>10</sup>

Some have speculated that adverse events following CSM are predictable and may be attributed to insufficient judgment and examination by the clinician.<sup>1</sup> It has been suggested that, when deciding whether or not to use CSM, a clinician should determine if the technique is both appropriate and safe.<sup>11,12</sup> CSM may be considered an appropriate treatment technique if it is indicated by the patient's presenting condition. Such

conditions indicating the use of CSM include neck pain, cervicogenic headache and cervical radiculopathy.<sup>12</sup> A 1996 study by the RAND group, examined the appropriateness of CSM by surveying the opinions of a nine member multidisciplinary expert panel. The panel was presented with clinical scenarios including patient history, symptoms, results from radiographic imaging and response to previous treatment. Patient conditions ranged from acute neck pain to cardiovascular pathology. The panel found CSM to be an appropriate technique to use in only 11.1% of the 736 clinical scenarios.<sup>12</sup> The study emphasized the importance of proper clinical reasoning, so as to not place a patient at risk for adverse event following CSM if they are not likely to benefit from the technique.

Once CSM is deemed to be appropriate for a patient's presenting condition, the clinician should determine the safety of the technique by identifying preexisting conditions that might indicate a patient's risk for adverse events. Absolute contraindications (table 1) and 'red flag' symptoms (table 2) have been identified to assist clinicians with decision-making.<sup>1</sup> 'Red flag' symptoms may indicate the presence of a contraindicated condition. CSM should never be performed when contraindicated conditions are present.<sup>1</sup> Childs et al (2005) recommend that contraindications and 'red flags' be used in conjunction with sound clinical reasoning as part of an examination scheme to assist in determining if CSM is an appropriate technique and to prevent adverse events due to CSM.<sup>11</sup>

While suggestions have been made to guide clinical reasoning and reduce the risk of adverse events following spinal manipulation, there have been few studies examining the use of these suggestions clinically.<sup>10,13</sup> Haldeman et al (2002) were unable to

recognize characteristics from a patient's history or examination that would indicate increased risk of CVA following CSM. To date, no study has investigated the use of examination procedures in patients experiencing adverse events other than CVA.

The purpose of the study was to retrospectively review all available documented case studies in the literature describing patients who had experienced severe adverse events after receiving CSM to determine if the CSM was used appropriately and if these types of adverse events could have been prevented using sound clinical reasoning on the part of the clinician. Our hypothesis was that, for reported cases of severe adverse events, CSM may have been used inappropriately and that those adverse events may have been prevented. Secondary analysis was performed to identify potential characteristics that may have put a patient at higher risk for an adverse event, as well as examine characteristics of cases leading to death.

## Methods

Case reports published in peer reviewed journals involving adverse events following CSM were found by searching PubMed (1950-2010) and the Cumulative Index to Nursing and Allied Health (CINHAL, 1982-2010). Initial search terms included any combination of the following: *cervical manipulation, adjustment, chiropractic, manual therapy, physical therapy, physiotherapy, osteopathy, arterial injury, stroke, safety, adverse event, side effect, injury and risk*. Additional case reports were obtained from references of articles cited by Di Fabio (1999), Ernst (2007) and Terrett (1987).

Titles and abstracts of articles identified with search terms were screened by two independent reviewers. One hundred and five (105) articles were identified and further

evaluated for inclusion and exclusion criteria by three reviewers. Articles were included if they provided one or more case reports and excluded if the adverse events occurred without CSM (e.g. spontaneous); if the condition for which CSM was used was not reported; or if it was written in a language other than English, German, Spanish, Polish, French or Norwegian. Ninety-three (93) articles, describing 134 cases, were determined to be eligible for final review.<sup>3,14-105</sup> Cases included in a language other than English were translated by native speakers or those fluent in the language prior to being evaluated. All case information was entered into a case analysis form which included: gender, age, who performed the CSM and why, presence of contraindications, the number of manipulations performed, initial symptoms experienced after the CSM, as well as type of adverse reaction that resulted.

All three reviewers completed a case analysis form and categorized each article individually. Based on the information gathered, CSMs were categorized as 'appropriate' or 'inappropriate', and adverse events were categorized as 'preventable', 'unpreventable' or 'unknown'. Appropriateness was based upon the patient's presenting condition. A case was determined to be 'appropriate' if CSM was used for an indicated condition such as neck pain, headache, or cervical radiculopathy and 'inappropriate' when CSM was performed for reasons that are not indicative to cervical disorders, such as low back pain, non-radicular shoulder pain or maintenance therapy. Preventability was based on the presence of factors that increase a patient's risk for injury. Cases were classified as 'preventable' when contraindications or red flags should have otherwise stopped the care provider from performing CSM and 'unpreventable' when the patient appeared to be clear of any contraindications or red flags to CSM either in current and/or past history

(see tables 1 & 2). Therefore, a CSM could have been performed for appropriate reasons, but if the clinician performed the CSM in the presence of contraindications or red flags, the adverse event would have been preventable. An 'unknown' category was created and used when an article did not provide enough information to allow it to be categorized as 'preventable' or 'unpreventable'. To improve accuracy of data, analysis of each case was then compared between all three reviewers and disagreements were resolved by consensus.

Once case reports had been categorized by 'appropriateness' and 'preventability', all reports were further categorized by severity of adverse reaction. These categories included: transient, severe reversible, and severe irreversible. Transient reactions were defined as symptoms that were minor and dissipated within 24 to 48 hours. Common transient reactions included: local increase in pain, headaches, fatigue, and radiating discomfort.<sup>4</sup> Severe, but reversible, reactions included disc herniation, nerve root compression and fracture. Severe, but irreversible, complications included dissection or vasospasticity of cervical arteries, causing CVA and death.<sup>4</sup> Additionally, cases found to be preventable were analyzed to determine the underlying condition for which it was placed in the preventability category.

All data collected from the analysis sheets were input to a spreadsheet and all statistics were performed using PASW 17.0 (SPSS 2009).<sup>\*</sup> Chi square analysis was used to determine if there was a difference in proportion between the six categories: appropriate/preventable, appropriate/unpreventable, appropriate/unknown, inappropriate/preventable, inappropriate/unpreventable and inappropriate/unknown.

---

<sup>\*</sup> PASW Statistics 2009 PASW statistics version 17.0. Chicago, IL: SPSS, Inc.



Further examination of these categories was done with frequency statistics. Demographic data and remaining data from the case analysis sheet were analyzed using descriptive and frequency statistics.

## Results

### Demographics

One hundred thirty four (134) cases, reported in 93 articles, were analyzed for this study. Language translation was required in 9% of the cases. The cases involved 73 males and 61 females. The average age was 43.8 years (SD=11.8, Range= 23 to 86 years).

Adverse events were categorized by severity of injury. Most of the injuries (51.5%, n=69) reported were categorized as severe and irreversible, while 41% (n= 55) were severe reversible, 5.2% (n=7) were transient, and 5.2% (n=7) were unknown.

Arterial dissection was the most common adverse event reported, being present in 34.5% of the cases (n=50). Other common adverse reactions included disc herniation (17.2%, n=25), CVA (12.4%, n=18), and vertebral dislocation or fracture (6.2%, n=9). The most common post-manipulation symptoms described were weakness (n=59), paresthesias (n=53), and increased pain (n=43) (Figure 1).

Chiropractic physicians were involved in the majority of injuries following CSM with 69% (n=93) of the cases analyzed (Figure 2). Physical therapists were involved in 4% (n=5) of the cases, while 11% (n=15) did not report the practitioner performing the CSM. Non-clinicians, including bone setters, barbers, and masseurs accounted for 7% (n=9) of the CSMs.

### Appropriateness and preventability

Chi-square analysis showed no significant difference in the proportions between appropriateness of the manipulation and preventability of adverse outcomes,  $\chi^2(2)=1.556$ ,  $p=.459$ . Of the cases analyzed, 19.4% (n=26) of the manipulations were categorized as inappropriate, 44.8% (n=60) of the adverse outcomes were preventable and 9% (n=12) of the cases were both inappropriate and preventable (Table 3).

Many of the cases categorized as preventable (49.2%, n=30) were determined to be so because of the presence of a preexisting condition in the cervical spine. Preexisting conditions present in the preventable cases consisted mostly (70%, n=21) of active bony pathologies including: severe spondylosis, osteoporosis, rheumatoid arthritis, ankylosing spondylitis, and cervical stenosis. Vascular pathologies, such as cardiac infarct and atherosclerosis of the cervical arteries, accounted for 13.3% (n=4) of preexisting conditions. Miscellaneous conditions, consisting of pregnancy, chronic symptoms from a motor vehicle accident 40 years prior and symptomatic disc pathology, accounted for 16.7% (n=5) of adverse events. Continued manipulation with either no change in presenting symptoms or worsening of symptoms occurred with a frequency of 24.6% (n=15) in both conditions.

### Cases resulting in death

Seven (5.2%) of the total cases ultimately resulted in death. Of the patients involved, 4 were male and 3 were female between the ages of 25 and 51. Practitioners involved in resulting death included: chiropractic physicians (71.4%, n=5), a naturopath (14.3%, n=1), and an unknown practitioner (14.3%, n=1). Arterial dissection was the cause of 5 deaths and CVA accounted for the remaining two. Four deaths were

determined to be preventable, 1 unpreventable and 2 unknown. Two of these cases resulting in death were categorized as preventable because the practitioner continued to perform manipulations when symptoms were worsening, and in the other 2 cases clinicians performed excessive (deemed greater than 3) manipulations with no change in symptoms.

## Discussion

There was no significant association between appropriateness of CSM and preventability of adverse events. Contrary to our hypothesis, CSMs that were performed inappropriately were not more likely to be classified as preventable. In fact, while 80.6% of all reviewed CSMs were performed for appropriate conditions, 44.8% of the cases were preventable and apparently not screened for contraindicating signs. These results suggest that simply determining that a CSM may be indicated is not sufficient to prevent adverse events. From a clinical perspective, a thorough examination to rule out all contraindications and 'red flags' may prevent nearly half of all adverse events related to CSM. Additionally, 19.4% of CSMs reviewed were performed for inappropriate conditions, meaning patients were placed at risk for adverse event although they were not likely to benefit from the technique.

Inability of clinicians to recognize signs indicating a patient is at increased risk may be attributed to the lack of reliable and valid screening tools, as well as poor history taking and insufficient clinical reasoning. The most common adverse reaction reported in these cases was arterial dissection. This finding has been well documented and as a result pre-manipulative screening tools have mostly focused on identifying vertebral basilar

insufficiency (VBI) to rule out risk of vertebral artery dissection associated with CSM, although use of these tests remain controversial.<sup>2,4,5,106-108</sup> The controversy stems from the high rate of false-positive results associated with these tools.<sup>108</sup> Westaway et al (2003) and Haldeman et al (2002) describe cases in which patients had VBI, but screening tools, consisting of end range extension and rotation of the cervical spine to evaluate vertebral artery patency, failed to provoke symptoms that would contraindicate CSM. In cases reviewed that were found to be preventable, clinicians may have excluded VBI testing due to conflicting evidence regarding its efficacy. However, it is also possible that clinicians had no intent to screen for contraindications due to lack of knowledge, poor clinical judgment or carelessness. Childs et al (2005) suggest that, regardless of the evidence, or lack thereof, it is the responsibility of the clinician to perform screening examinations and clearly document their use to reduce legal risk if an adverse event were to occur with CSM.

With uncertainty regarding screening tools, clinicians must use additional strategies (e.g., red flags) for decision making when choosing to use CSM.<sup>11</sup> Most of the cases reviewed were classified as preventable due to inability of the clinician to recognize red flag symptoms of preexisting conditions that would contraindicate the use of CSM. The most common preexisting conditions were found to be bony pathologies such as severe osteoporosis, spondylosis and rheumatoid arthritis. These conditions are clear contraindications to CSM and should have been easily identifiable through a detailed patient history. With the lack of accurate screening tools, it is prudent for the clinician to perform a thorough history to ensure patient safety.<sup>11</sup> Childs et al (2005) suggest that clinicians should use not only clinical reasoning to determine whether or not CSM is

appropriate and safe, but they should also consider their own skill level, the preferences of the referring provider, as well as the demeanor and goals of the patient.

While most of the cases of adverse events were classified as preventable, 10.4% of cases were found to be unpreventable. Considering reported incidence figures, adverse events following CSM are uncommon at 1 per 50,000, indicating that unpreventable adverse events are even more uncommon. Though millions of CSMs are performed without adverse events, the results suggest a very small but inherent risk associated with CSM even after a thorough examination for contraindications and proper clinical reasoning. The findings are consistent with conclusions made by Haldeman et al (2002), but may also reflect the inability of examination procedures to detect patients at risk for adverse events.

Demographics of the patient population were comparable to those reported in previous literature, with one disparity consisting of gender ratios being skewed more toward male than female.<sup>2,8,9</sup> In this study, the majority of adverse events were categorized as severe and irreversible. However, according to current literature, transient side effects are more common than severe adverse reactions.<sup>109</sup> In fact, transient side effects are reported to occur in 55% of all CSMs.<sup>110,111</sup> The discrepancy in representation of severity is likely because transient side effects tend to be under-reported. Severe complications are more likely to require medical attention and, therefore, be documented.<sup>112</sup> Additionally, the purpose of this study was to review cases with severe adverse events rather than transient reactions following CSM.

The distribution of clinicians in our study mirrors those described by both Di Fabio (1999) and Ernst (2007). Chiropractors were found to be involved with the

majority of severe adverse events resulting from CSM. This result may be because CSM is the most common treatment modality used in Chiropractics and is performed more frequently by chiropractors than any other clinician. Osteopaths and physical therapists were also involved in 11% and 4%, respectively, of the adverse events associated with CSM in the current study. Presumably, osteopaths and physical therapists may be involved in a lower percentage since both professions have a wide range of practices not only in orthopedic spinal conditions (e.g., neurological, cardiac, respiratory, acute care) where CSM may not be appropriate.

The incidences of severe injuries resulting from CSM have been estimated to be uncommon, with injuries resulting in death even less common.<sup>6,7</sup> Of the cases analyzed, death occurred in only 5.2% compared to 18% as reported by Di Fabio (1999). This discrepancy may be attributed to differences in the results of the literature search. The most recent case of death included in the present study was reported in 1995, which may indicate either a lower incidence of death resulting from CSM or a lack of reporting of such incidences in recent years. Other factors that may have contributed include: a paucity of reports written by clinicians regarding death after CSM, search methods may not have been sufficient to identify more recent cases of death, and stipulations of settlements on litigated cases may have not allowed information regarding the case to be made public. Most deaths were related to CSM by chiropractors, which reflected the percentage of chiropractors involved in total CSMs. Chiropractors were involved in 71% of the deaths which mirrors the 70% of the total adverse events that were associated with chiropractors performing the CSM. As stated previously, this finding is likely because CSM and spinal manipulation are the foundation of chiropractic treatment.

All deaths were related to either arterial dissection or CVA. It is well known that CVA and arterial dissection are closely related and it is possible that the cases of CVA may have also been caused by arterial dissection that was missed upon examination.<sup>113</sup> Although many factors may lead to serious complications, arterial dissection is potentially the most serious and life threatening complication resulting from CSM.

Four cases of death were found to be preventable. Of these cases, two patients received multiple manipulations with no improvement in symptoms.<sup>64,88</sup> The first patient received at least 19 CSMs in four months without change in presenting headache symptoms, while the second patient was receiving CSM maintenance therapy over multiple years with no improvement of symptoms.<sup>64,88</sup> These cases indicate that repeated CSMs may cause damage to the vessels over time. While no human studies have been conducted, Austin et al (2010) was unable to refute or support the idea that micro-damage occurs to arterial vessels with repeated CSM in his animal model study.<sup>114</sup> The third patient experienced symptoms of vertebrobasilar ischemia following CSM including dizziness, severe headache, and nausea, but was treated with another CSM one hour later resulting in loss of consciousness and cessation of breathing.<sup>48</sup> The final patient was noted to have a red flag symptom of vertigo, prior to receiving CSM.<sup>73</sup> In these cases, the clinician ignored symptoms indicating the patient was at risk for serious injury. Although evidence for VBI testing and related symptoms are lacking, it is unwise for clinicians to disregard these symptoms and continue to perform CSM in their presence.<sup>11</sup>

One limitation of our study was that the definitions of the categories for appropriateness and preventability were not standardized and the interpretations of case reports, as well as the placement of them into suitable categories, were areas of

subjectivity. Also, the search for relevant case reports may not have been exhaustive. There may have been discrepancies between what was reported in the case report and what actually occurred, as physicians, rather than the clinician performing the CSM, published many of the cases. Missing information needed for the analysis of cases resulted in the exclusion or placement of a large proportion (44.8%) of cases into an unknown category, which may have had an influence on the results of the statistical analyses. When the term ‘chiropractic manipulation’ was used in the case reports, it was assumed that the clinician performing CSM was a chiropractor. However, Di Fabio (1999) stated that the term ‘chiropractic manipulation’ was occasionally used when other clinicians were performing the CSM.<sup>2</sup> Additionally, relying on secondary sources for translation of non-English articles may have led to misinterpretation by the translators as well as the reviewers.

This study presented initial definitions for appropriateness of CSM and preventability of adverse events. Future research should standardize these definitions, as well as definitions regarding manipulation. Additionally, an objective recording system should be developed to determine the true incidence of adverse events related to CSM.<sup>109,115</sup> By utilizing standardized definitions and an objective recording system, stronger evidence can be produced, with a reduction in limitations.

We propose that case reports regarding adverse reactions to CSM provide standardized information. This should include detailed information regarding the manipulation technique, as proposed by Mintken et al (2008).<sup>116</sup> The six categories suggested include: rate of force application, location in range of available movement, direction of force, target of force, relative structural movement, and patient position.<sup>116</sup>



Additionally, case reports should include: number of CSMs performed for the present condition, for what condition the CSM was performed, which clinician performed the CSM, and a description of examination procedures to rule out contraindications and red flags. These details would provide a comprehensive description of the adverse event, which would reduce assumptions during analysis of cases for future research.

With VBI testing being unreliable, it is necessary for future research to develop reliable and valid screening tools to better help clinicians identify red flags and contraindications when present.<sup>10,108,117</sup> These tools should be accessible and efficient so that they may be incorporated easily into an examination scheme. Future research should also look for an association between CSM and micro-trauma to the cervical arteries, to determine if multiple manipulations cause damage to the arterial vessels, which may put one at greater risk for arterial dissection. This may assist in identifying a maximum number of CSMs that a clinician should perform without change in symptoms before choosing an alternative treatment technique.

### Conclusion

If all contraindications and red flags have been ruled out, there is potential for a clinician to prevent 44.8% of adverse events associated with CSM. Additionally, 10.4% of the events were unpreventable, suggesting some inherent risk associated with CSM even after a thorough exam and proper clinical reasoning. By performing a thorough examination and using sound clinical reasoning, clinicians may be able to prevent a majority of adverse events, further reducing risks associated with CSM and improving patient safety.

## References

1. Refshauge KM, Parry S, Shirley D, Larsen D, Rivett DA, Boland R. Professional responsibility in relation to cervical spine manipulation. *Aust J Physiother.* 2002;48(3):171-179; discussion 180-175.
2. Di Fabio RP. Manipulation of the cervical spine: risks and benefits. *Phys Ther.* Jan 1999;79(1):50-65.
3. Gouveia LO, Castanho P, Ferreira JJ, Guedes MM, Falcao F, e Melo TP. Chiropractic manipulation: reasons for concern? *Clin Neurol Neurosurg.* Dec 2007;109(10):922-925.
4. Paciaroni M, Bogousslavsky J. Cerebrovascular complications of neck manipulation. *Eur Neurol.* 2009;61(2):112-118.
5. Rivett DA. Adverse events and the vertebral artery: can they be averted? *Man Ther.* Nov 2006;11(4):241-242.
6. Haldeman S, Carey P, Townsend M, Papadopoulos C. Arterial dissections following cervical manipulation: the chiropractic experience. *CMAJ.* Oct 2 2001;165(7):905-906.
7. Magarey ME, Rebbeck T, Coughlan B, Grimmer K, Rivett DA, Refshauge K. Pre-manipulative testing of the cervical spine review, revision and new clinical guidelines. *Man Ther.* May 2004;9(2):95-108.
8. Ernst E. Manipulation of the cervical spine: a systematic review of case reports of serious adverse events, 1995-2001. *Med J Aust.* Apr 15 2002;176(8):376-380.
9. Ernst E. Adverse effects of spinal manipulation: a systematic review. *J R Soc Med.* Jul 2007;100(7):330-338.
10. Haldeman S, Kohlbeck FJ, McGregor M. Unpredictability of cerebrovascular ischemia associated with cervical spine manipulation therapy: a review of sixty-four cases after cervical spine manipulation. *Spine (Phila Pa 1976).* Jan 1 2002;27(1):49-55.
11. Childs JD, Flynn TW, Fritz JM, et al. Screening for vertebrobasilar insufficiency in patients with neck pain: manual therapy decision-making in the presence of uncertainty. *J Orthop Sports Phys Ther.* May 2005;35(5):300-306.
12. Coulter I, Adams A, Shekelle P. Impact of varying panel membership on ratings of appropriateness in consensus panels: a comparison of a multi- and single disciplinary panel. *Health Serv Res.* Oct 1995;30(4):577-591.
13. Shekelle PG, Hurwitz EL, Coulter I, Adams AH, Genovese B, Brook RH. The appropriateness of chiropractic spinal manipulation for low back pain: a pilot study. *J Manipulative Physiol Ther.* Jun 1995;18(5):265-270.
14. Beatty RA. Dissecting hematoma of the internal carotid artery following chiropractic cervical manipulation. *J Trauma.* 1977;17:248-249.
15. Braun IF, Pinto RS, De Filipp GJ, Lieberman A, Pasternack P, Zimmerman RD. Brain stem infarction due to chiropractic manipulation of the cervical spine. *South Med J.* Dec 1983;76(12):1507-1510.
16. Braune HJ, Munk MH, Huffmann G. Cerebral infarct in the circulatory area of the arteria cerebri media following chiropractic therapy of the cervical spine. *Dtsch Med Wochenschr.* Jul 5 1991;116(27):1047-1050.
17. Brownson RJ, Zollinger WK, Madeira T, Fell D. Sudden sensorineural hearing loss following manipulation of the cervical spine. *Laryngoscope.* 1986;96(2):166-170.
18. Cellerier P, Georget AM. Dissection of the vertebral arteries after manipulation of the cervical spine. Apropos of a case. *J Radiol.* Mar 1984;65(3):191-196.
19. Chen WL, Chern CH, Wu YL, Lee CH. Vertebral artery dissection and cerebellar infarction following chiropractic manipulation. *Emerg Med J.* Jan 2006;23(1):e1.
20. Chung OM. MRI confirmed cervical cord injury caused by spinal manipulation in a Chinese patient. *Spinal Cord.* Apr 2002;40(4):196-199.
21. Cook JWt, Sanstead JK. Wallenberg's syndrome following self-induced manipulation. *Neurology.* Oct 1991;41(10):1695-1696.

22. Devereaux MW. The neuro-ophthalmologic complications of cervical manipulation. *J Neuroophthalmol*. Dec 2000;20(4):236-239.
23. Domenicucci M, Ramieri A, Salvati M, Brogna C, Raco A. Cervicothoracic epidural hematoma after chiropractic spinal manipulation therapy. Case report and review of the literature. *J Neurosurg Spine*. Nov 2007;7(5):571-574.
24. Donovan JS, Kerber CW, Donovan WH, Marshall LF. Development of spontaneous intracranial hypotension concurrent with grade IV mobilization of the cervical and thoracic spine: a case report. *Arch Phys Med Rehabil*. Nov 2007;88(11):1472-1473.
25. Dunne JW, Conacher GN, Khangure M, Harper CG. Dissecting aneurysms of the vertebral arteries following cervical manipulation: a case report. *J Neurol Neurosurg Psychiatry*. 1987;50:349-353.
26. Ea HK, Weber AJ, Yon F, Liote F. Osteoporotic fracture of the dens revealed by cervical manipulation. *Joint Bone Spine*. May 2004;71(3):246-250.
27. Easton JD, Sherman DG. Cervical manipulation and stroke. *Stroke*. Sep-Oct 1977;8(5):594-597.
28. Frisoni GB, Anzola GP. Vertebrobasilar ischemia after neck motion. *Stroke*. Nov 1991;22(11):1452-1460.
29. Fritz VU, Maloon A, Tuch P. Neck manipulation causing stroke. Case reports. *S Afr Med J*. Dec 1 1984;66(22):844-846.
30. Frumkin LR, Baloh RW. Wallenberg's syndrome following neck manipulation. *Neurology*. Apr 1990;40(4):611-615.
31. Gittinger JW, Jr. Occipital infarction following chiropractic cervical manipulation. *J Clin Neuroophthalmol*. Mar 1986;6(1):11-13.
32. Grayson M. Horner's syndrome after manipulation of the neck. *BMJ*. 1987;295:1381-1382.
33. Heffner JE. Diaphragmatic paralysis following chiropractic manipulation of the cervical spine. *Arch Intern Med*. Mar 1985;145(3):562-564.
34. Heiner JD. Cervical epidural hematoma after chiropractic spinal manipulation. *Am J Emerg Med*. Oct 2009;27(8):1023 e1021-1022.
35. Hillier CE, Gross ML. Sudden onset vomiting and vertigo following chiropractic neck manipulation. *Postgrad Med J*. Sep 1998;74(875):567-568.
36. Hinse P, Thie A, Lachenmayer L. Dissection of the extracranial vertebral artery: report of four cases and review of the literature. *J Neurol Neurosurg Psychiatry*. Oct 1991;54(10):863-869.
37. Hoffelner T, Maurer-Ertl W, Kienbacher G, Radl R, Leithner A, Windhager R. Internal jugular vein thrombosis following cervical manipulation. *Man Ther*. Dec 2009;14(6):706-708.
38. Horn SW, 2nd. The "Locked-In" syndrome following chiropractic manipulation of the cervical spine. *Ann Emerg Med*. Oct 1983;12(10):648-650.
39. Hsieh JH, Wu CT, Lee ST. Cervical intradural disc herniation after spinal manipulation therapy in a patient with ossification of posterior longitudinal ligament: a case report and review of the literature. *Spine (Phila Pa 1976)*. Mar 1 2010;35(5):E149-151.
40. Jay WM, Shah MI, Schneck MJ. Bilateral occipital-parietal hemorrhagic infarctions following chiropractic cervical manipulation. *Semin Ophthalmol*. Dec 2003;18(4):205-209.
41. Jentzen JM, Amatuzio J, Peterson GF. Complications of cervical manipulation: a case report of fatal brainstem infarct with review of the mechanisms and predisposing factors. *J Forensic Sci*. Jul 1987;32(4):1089-1094.
42. Jeret JS, Bluth M. Stroke following chiropractic manipulation. Report of 3 cases and review of the literature. *Cerebrovasc Dis*. 2002;13(3):210-213.

43. Kanschepolsky J, Danielson H, Flynn RE. Vertebral artery insufficiency and cerebellar infarct due to manipulation of the neck. Report of a case. *Bull Los Angeles Neurol Soc.* Apr 1972;37(2):62-65.
44. Katirji MB, Reinmuth OM, Latchaw RE. Stroke due to vertebral artery injury. *Arch Neurol.* Mar 1985;42(3):242-248.
45. Khan AM, Ahmad N, Li X, Korsten MA, Rosman A. Chiropractic sympathectomy: carotid artery dissection with oculosympathetic palsy after chiropractic manipulation of the neck. *Mt Sinai J Med.* May 2005;72(3):207-210.
46. Kraft CN, Conrad R, Vahlensieck M, Perlick L, Schmitt O, Diedrich O. Non-cerebrovascular complication in chirotherapy manipulation of cervical vertebra. *Z Orthop Ihre Grenzgeb.* 2001;139(1):8-11.
47. Krieger D, Leibold M, Bruckmann H. Dissections of the vertebral artery following cervical chiropractic manipulations. *Dtsch Med Wochenschr.* Apr 13 1990;115(15):580-583.
48. Krueger BR, Okazaki H. Vertebral-basilar distribution infarction following chiropractic cervical manipulation. *Mayo Clin Proc.* May 1980;55(5):322-332.
49. Kunkle EC, Muller JC, Odom GL. Traumatic brain-stem thrombosis: report of a case and analysis of the mechanism of injury. *Ann Intern Med.* May 1952;36(5):1329-1335.
50. Kurbanyan K, Lessell S. Intracranial hypotension and abducens palsy following upper spinal manipulation. *Br J Ophthalmol.* Jan 2008;92(1):153-155.
51. Lennington BR, Laster DW, Moody DM, Ball MR. Traumatic pseudoaneurysm of ascending cervical artery in neurofibromatosis: complication of chiropractic manipulation. *AJNR Am J Neuroradiol.* May-Jun 1980;1(3):269-270.
52. Liao CC, Chen LR. Anterior and Posterior Fixation of a Cervical Fracture Induced by Chiropractic Spinal Manipulation in Ankylosing Spondylitis: A Case Report. *J Trauma.* 2007;63:E90-E94.
53. Lipper MH, Goldstein JH, Do HM. Brown-Sequard syndrome of the cervical spinal cord after chiropractic manipulation. *AJNR Am J Neuroradiol.* Aug 1998;19(7):1349-1352.
54. Ludwig SC, Vaccaro AR, Balderston RA, Cotler JM. Immediate quadriplegia after manipulation for bilateral cervical facet subluxation. A case report. *J Bone Joint Surg Am.* Apr 1997;79(4):587-590.
55. Malone DG, Baldwin NG, Tomecek FJ, et al. Complications of cervical spine manipulation therapy: 5-year retrospective study in a single-group practice. *Neurosurg Focus.* Dec 15 2002;13(6):ecp1.
56. Mas JL, Henin D, Bousser MG, Chain F, Hauw JJ. Dissecting aneurysm of the vertebral artery and cervical manipulation: a case report with autopsy. *Neurology.* Apr 1989;39(4):512-515.
57. Mendel T, Baranska-Gieruszczak M. Brain stem syndrome after cervical chiropractic manipulations. *Neurol Neurochir Pol.* Jul-Aug 2001;35(4):695-699.
58. Menendez-Gonzalez M, Garcia C, Suarez E, Fernandez-Diaz D, Blazquez-Menes B. Wallenberg's syndrome secondary to dissection of the vertebral artery caused by chiropractic manipulation. *Rev Neurol.* Nov 1-15 2003;37(9):837-839.
59. Morelli N, Gallerini S, Gori S, et al. Intracranial hypotension syndrome following chiropractic manipulation of the cervical spine. *J Headache Pain.* Sep 2006;7(4):211-213.
60. Mueller S, Sahs AL. Brain stem dysfunction related to cervical manipulation. Report of three cases. *Neurology.* Jun 1976;26(6 PT 1):547-550.
61. Murphy DR. Herniated disc with radiculopathy following cervical manipulation: nonsurgical management. *Spine J.* Jul-Aug 2006;6(4):459-463.
62. Murthy JM, Naidu KV. Aneurysm of the cervical internal carotid artery following chiropractic manipulation. *J Neurol Neurosurg Psychiatry.* Sep 1988;51(9):1237-1238.

63. Nadgir RN, Loevner LA, Ahmed T, et al. Simultaneous bilateral internal carotid and vertebral artery dissection following chiropractic manipulation: case report and review of the literature. *Neuroradiology*. May 2003;45(5):311-314.
64. Nyberg-Hansen R, Loken AC, Tenstad O. Brainstem lesion with coma for five years following manipulation of the cervical spine. *J Neurol*. May 18 1978;218(2):97-105.
65. Oehler J, Gandjour J, Fiebach J, Schwab S. Bilateral vertebral artery dissection after chiropractic treatment. *Orthopade*. Oct 2003;32(10):911-913; discussion 914-915.
66. Oppenheim JS, Spitzer DE, Segal DH. Nonvascular complications following spinal manipulation. *Spine J*. Nov-Dec 2005;5(6):660-666; discussion 666-667.
67. Padua L, Padua R, LoMonaco M, Tonali PA. Radiculomedullary complications of cervical spinal manipulation. *Spinal Cord*. Aug 1996;34(8):488-492.
68. Panagariya A, Kumawat BL, Singh R, Sukhani P. Total unilateral medullary syndrome--a rare complication of chiropractic manipulation. *J Assoc Physicians India*. Jul 2004;52:556.
69. Parenti G, Orlandi G, Bianchi M, Renna M, Martini A, Murri L. Vertebral and carotid artery dissection following chiropractic cervical manipulation. *Neurosurg Rev*. Oct 1999;22(2-3):127-129.
70. Parkin PJ, Wallis WE, Wilson JL. Vertebral artery occlusion following manipulation of the neck. *N Z Med J*. Dec 13 1978;88(625):441-443.
71. Parwar BL, Fawzi AA, Arnold AC, Schwartz SD. Horner's syndrome and dissection of the internal carotid artery after chiropractic manipulation of the neck. *Am J Ophthalmol*. Apr 2001;131(4):523-524.
72. Patel A, Lee R, Fritz W, Matos E, Freeman JW. Vertebral artery dissection from cervical spine manipulation: case reports and analysis. *S D Med*. Mar 2008;61(3):95, 97-99.
73. Peters M, Bohl J, Thomke F, et al. Dissection of the internal carotid artery after chiropractic manipulation of the neck. *Neurology*. Dec 1995;45(12):2284-2286.
74. Phillips SJ, Maloney WJ, Gray J. Pure motor stroke due to vertebral artery dissection. *Can J Neurol Sci*. Aug 1989;16(3):348-351.
75. Povlsen UJ, Kjaer L, Arlien-Soborg P. Locked-in syndrome following cervical manipulation. *Acta Neurol Scand*. Dec 1987;76(6):486-488.
76. Powell FC, Hanigan WC, Olivero WC. A risk/benefit analysis of spinal manipulation therapy for relief of lumbar or cervical pain. *Neurosurgery*. Jul 1993;33(1):73-78; discussion 78-79.
77. Prasad S, El-Haddad G, Zhuang H, Khella S. Intracranial hypotension following chiropractic spinal manipulation. *Headache*. Oct 2006;46(9):1456-1458.
78. Pribek RA. Brain stem vascular accident following neck manipulation. *Wis Med J*. Mar 1963;62:141-143.
79. Putnam TD, Wu Y. Tracheal rupture following cervical manipulation: late complication posttracheostomy. *Arch Phys Med Rehabil*. Jan 1986;67(1):48-50.
80. Quintana JG, Drew EC, Richtsmeier TE, Davis LE. Vertebral artery dissection and stroke following neck manipulation by Native American healer. *Neurology*. May 14 2002;58(9):1434-1435.
81. Raskind R, North CM. Vertebral artery injuries following chiropractic cervical spine manipulation--case reports. *Angiology*. Jun 1990;41(6):445-452.
82. Rinsky LA, Reynolds GG, Jameson RM, Hamilton RD. A cervical spinal cord injury following chiropractic manipulation. *Paraplegia*. Feb 1976;13(4):223-227.
83. Schellhas KP, Latchaw RE, Wendling LR, Gold LH. Vertebrobasilar injuries following cervical manipulation. *Jama*. Sep 26 1980;244(13):1450-1453.
84. Schmitz A, Lutterbey G, von Engelhardt L, von Falkenhausen M, Stoffel M. Pathological cervical fracture after spinal manipulation in a pregnant patient. *J Manipulative Physiol Ther*. Oct 2005;28(8):633-636.

85. Schram DJ, Vosik W, Cantral D. Diaphragmatic paralysis following cervical chiropractic manipulation: case report and review. *Chest*. Feb 2001;119(2):638-640.
86. Sedat J, Dib M, Mahagne MH, Lonjon M, Paquis P. Stroke after chiropractic manipulation as a result of extracranial postero-inferior cerebellar artery dissection. *J Manipulative Physiol Ther*. Nov-Dec 2002;25(9):588-590.
87. Segal DH, Lidov MW, Camins MB. Cervical epidural hematoma after chiropractic manipulation in a healthy young woman: case report. *Neurosurgery*. Nov 1996;39(5):1043-1045.
88. Sherman MR, Smialek JE, Zane WE. Pathogenesis of vertebral artery occlusion following cervical spine manipulation. *Arch Pathol Lab Med*. Sep 1987;111(9):851-853.
89. Sinel M, Smith D. Thalamic infarction secondary to cervical manipulation. *Arch Phys Med Rehabil*. May 1993;74(5):543-546.
90. Sivakumaran P, Wilsher M. Diaphragmatic palsy and chiropractic manipulation. *N Z Med J*. Jul 14 1995;108(1003):279-280.
91. Smith RA, Estridge MN. Neurologic complications of head and neck manipulations. *Jama*. Nov 3 1962;182:528-531.
92. Soper JR, Parker GD, Hallinan JM. Vertebral artery dissection diagnosed with CT. *AJNR Am J Neuroradiol*. Apr 1995;16(4 Suppl):952-954.
93. Sturzenegger M. Vertebral artery dissection following manipulation of the cervical vertebrae. *Schweiz Med Wochenschr*. Jul 13 1993;123(27-28):1389-1399.
94. Suh SI, Koh SB, Choi EJ, et al. Intracranial hypotension induced by cervical spine chiropractic manipulation. *Spine*. Jun 15 2005;30(12):E340-342.
95. Tinel D, Bliznakova E, Juhel C, Gallien P, Brissot R. Vertebrobasilar ischemia after cervical spine manipulation: a case report. *Ann Readapt Med Phys*. Jun 2008;51(5):403-414.
96. Tolge C, Iyer V, McConnell J. Phrenic nerve palsy accompanying chiropractic manipulation of the neck. *South Med J*. Jun 1993;86(6):688-690.
97. Tseng SH, Chen Y, Lin SM, Wang CH. Cervical epidural hematoma after spinal manipulation therapy: case report. *J Trauma*. Mar 2002;52(3):585-586.
98. Tseng SH, Lin SM, Chen Y, Wang CH. Ruptured cervical disc after spinal manipulation therapy: report of two cases. *Spine (Phila Pa 1976)*. Feb 1 2002;27(3):E80-82.
99. Vibert D, Rohr- Le Floch J, Gauthier G. Vertigo as manifestation of vertebral artery dissection after chiropractic neck manipulations. *Journal for Oto-Rhino-Laryngology*. 1993;55:140-142.
100. Wang JL, Lin JJ, Lin JC, Lie CC, Shih TP, Tsao WL. Vertebral artery dissection complicated by cervical manipulation: a case report. *Zhonghua Yi Xue Za Zhi (Taipei)*. Jun 1995;55(6):496-500.
101. Weintraub MI. Dormant foramen magnum meningioma 'activated' by chiropractic manipulation. *N Y State J Med*. Jul-Sep 1983;83(8-10):1039-1040.
102. Whedon JM, Quebada PB, Roberts DW, Radwan TA. Spinal epidural hematoma after spinal manipulative therapy in a patient undergoing anticoagulant therapy: a case report. *J Manipulative Physiol Ther*. Sep 2006;29(7):582-585.
103. Wood MJ, Lang EK, Woolhandler GJ, Faludi HK. Traumatic vertebral artery thrombosis. *J La State Med Soc*. Dec 1971;123(12):413-414.
104. Young YH, Chen CH. Acute vertigo following cervical manipulation. *Laryngoscope*. Apr 2003;113(4):659-662.
105. Zupruk GM, Mehta Z. Brown-Sequard syndrome associated with posttraumatic cervical epidural hematoma: case report and review of the literature. *Neurosurgery*. Aug 1989;25(2):278-280.
106. Bolton PS, Stick PE, Lord RS. Failure of clinical tests to predict cerebral ischemia before neck manipulation. *J Manipulative Physiol Ther*. Aug 1989;12(4):304-307.

107. Thiel H, Rix G. Is it time to stop functional pre-manipulation testing of the cervical spine? *Man Ther.* May 2005;10(2):154-158.
108. Westaway MD, Stratford P, Symons B. False-negative extension/rotation pre-manipulative screening test on a patient with an atretic and hypoplastic vertebral artery. *Man Ther.* May 2003;8(2):120-127.
109. Thiel HW, Bolton JE, Docherty S, Portlock JC. Safety of chiropractic manipulation of the cervical spine: a prospective national survey. *Spine* 2007;32(31):2375-2378.
110. Cagnie B, Vinck E, Beernaert A, Cambier D. How common are side effects of spinal manipulation and can these side effects be predicted? *Man Ther.* Aug 2004;9(3):151-156.
111. Senstad O, Leboeuf-Yde C, Borchgrevink C. Frequency and characteristics of side effects of spinal manipulative therapy. *Spine (Phila Pa 1976)*. Feb 15 1997;22(4):435-440; discussion 440-431.
112. Ernst E. Prospective investigations into the safety of spinal manipulation. *J Pain Symptom Manage.* Mar 2001;21(3):238-242.
113. Schwartz NE, Vertinsky AT, Hirsch KG, Albers GW. Clinical and radiographic natural history of cervical artery dissections. *J Stroke Cerebrovasc Dis.* Nov-Dec 2009;18(6):416-423.
114. Austin N, DiFrancesco LM, Herzog W. Microstructural damage in arterial tissue exposed to repeated tensile strains. *J Manipulative Physiol Ther.* Jan;33(1):14-19.
115. Carlesso L, Macdermid JC, Santaguida L. Standardization of Adverse Event Terminology and Reporting in Orthopaedic Physical Therapy - Applications to the Cervical Spine. *J Orthop Sports Phys Ther.* May 13 2010.
116. Mintken PE, Derosa C, Little T, Smith B. A Model for Standardizing Manipulation Terminology in Physical Therapy Practice. *J Man Manip Ther.* 2008;16(1):50-56.
117. Rivett DA, Sharples KJ, Milburn PD. Effect of premanipulative tests on vertebral artery and internal carotid artery blood flow: a pilot study. *J Manipulative Physiol Ther.* Jul-Aug 1999;22(6):368-375.

**Table 1.**

---

<b>Absolute contraindications to performing CSM</b>	
Acute fracture	Acute soft tissue injury
Dislocation	Osteoporosis
Ligamentous rupture	Ankylosing spondylitis
Instability	Rheumatoid arthritis
Tumor	Vascular disease
Infection	Vertebral artery abnormalities
Acute myelopathy	Connective tissue disease
Recent surgery	Anitcoagulant therapy

---



**Table 2.**

---

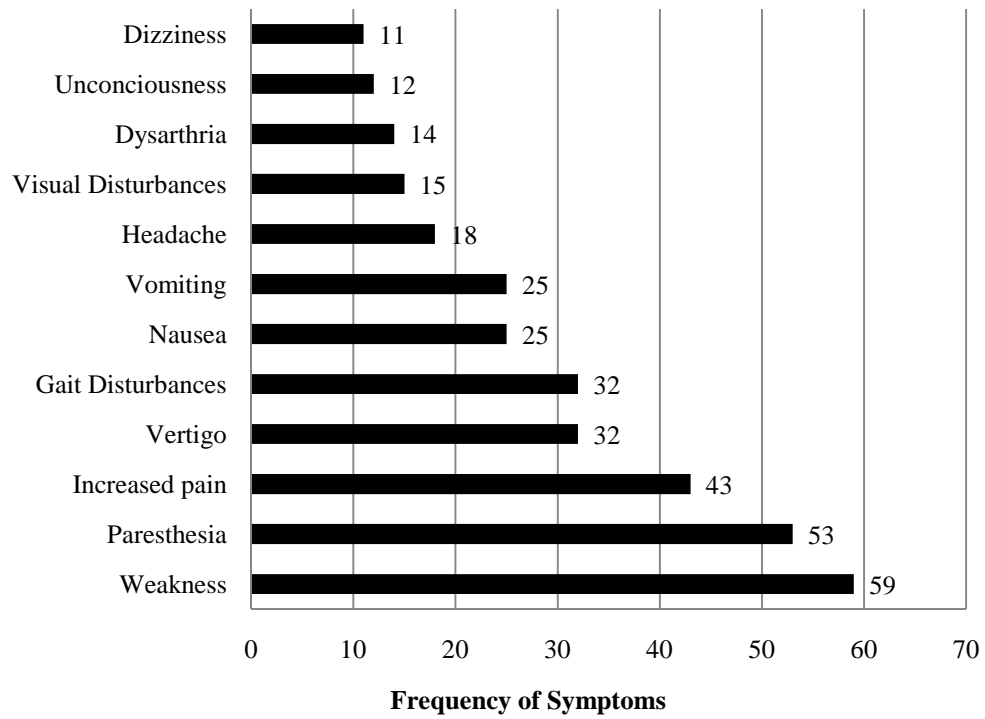
<b>Red Flags</b>
Previous diagnosis of vertebrobasilar insufficiency
Facial/intra-oral anaesthesia or paresthesia
Visual disturbances
Dizziness/vertigo
Blurred vision
Diplopia
Nausea
Tinnitus
Drop attacks
Dysarthria
Dysphagia
Any symptom listed above aggravated by position or movement of the neck
No change or worsening of symptoms after multiple manipulations

---

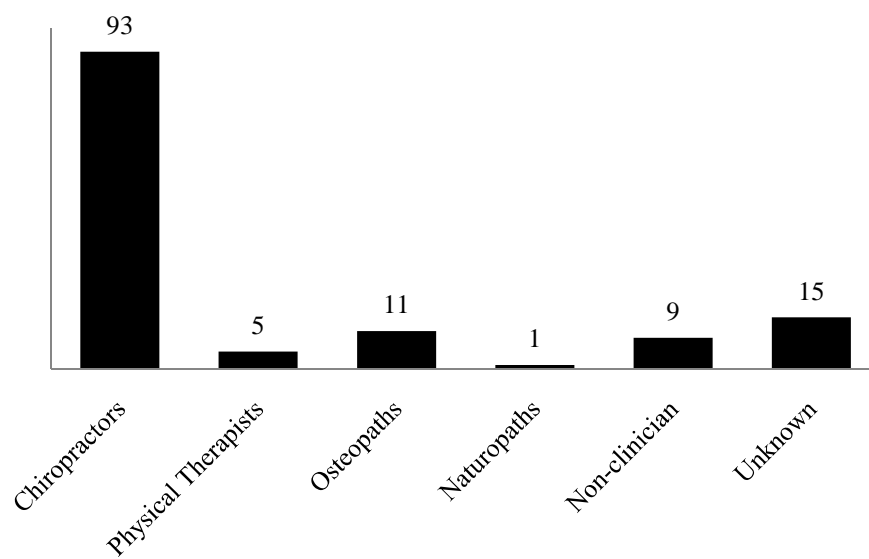
**Table 3.** Distribution of cases categorized by appropriateness and preventability

	<b>Appropriate</b>	<b>Inappropriate</b>	<b>Total</b>
<b>Preventable</b>	<b>48</b> <b>35.8%</b>	<b>12</b> <b>9.0%</b>	60 44.8%
<b>Unpreventable</b>	<b>13</b> <b>9.7%</b>	<b>1</b> <b>0.7%</b>	14 10.4%
<b>Unknown</b>	<b>47</b> <b>35.1%</b>	<b>13</b> <b>9.7%</b>	60 44.8%
<b>Total</b>	108 80.6%	26 19.4%	134 100.0%

**Figure 1.** Frequency of symptoms associated with adverse events following CSM



**Figure 2.** Frequency of practitioners performing CSM in cases of adverse events





## Biomedical IRB –Review Notice of Excluded Activity

**DATE:** June 9, 2009

**TO:** Dr. Louie Puentedura, Physical Therapy

**FROM:** Office for the Protection of Research Subjects

**RE:** Notification of IRB Action by Dr. John Mercer, Chair  
Protocol Title: **The Safety of Cervical Spine Manipulation: Are Adverse Events Predictable and/or Preventable?**  
OPRS# 0905-3116

---

This memorandum is notification that the project referenced above has been reviewed by the UNLV Biomedical Institutional Review Board (IRB) as indicated in Federal regulatory statutes 45CFR46.

The protocol has been reviewed and deemed excluded from IRB review. It is not in need of further review or approval by the IRB.

*Any changes to the excluded activity may cause this project to require a different level of IRB review. Should any changes need to be made, please submit a Modification Form.*

If you have questions or require any assistance, please contact the Office for the Protection of Research Subjects at [OPRSHumanSubjects@unlv.edu](mailto:OPRSHumanSubjects@unlv.edu) or call 895-2794.

VITA

Graduate College  
University of Nevada, Las Vegas

Amber Perez

Degrees:

Bachelor of Science, Kinesiology 2008  
University of Nevada-Las Vegas

Dissertation Title: Safety of Cervical Manipulation: Are Adverse Events Preventable and Are Manipulations Being Performed Appropriately?

Dissertation Examination Committee:

Research Advisor, Louie Puentedura, PT, DPT, GDMT, OCS, FAAOMPT  
Research Project Coordinator, Merrill Landers, DPT, OCS,  
Department Chair, Harvey Wallmann, PT, DSc, SCS, LAT, ATC, CSCS