

5-1-2017

## Measurement of Anterior Translation of the Mandibular Condyle Using Ultrasonography

Brooke Laskowski  
*University of Nevada, Las Vegas*

Danielle Hahn  
*University of Nevada, Las Vegas*

Christensen J. Hardy  
*University of Nevada, Las Vegas*

Follow this and additional works at: <https://digitalscholarship.unlv.edu/thesesdissertations>

 Part of the [Physical Therapy Commons](#)

---

### Repository Citation

Laskowski, Brooke; Hahn, Danielle; and Hardy, Christensen J., "Measurement of Anterior Translation of the Mandibular Condyle Using Ultrasonography" (2017). *UNLV Theses, Dissertations, Professional Papers, and Capstones*. 2929.  
<http://dx.doi.org/10.34917/10983015>

This Dissertation is protected by copyright and/or related rights. It has been brought to you by Digital Scholarship@UNLV with permission from the rights-holder(s). You are free to use this Dissertation in any way that is permitted by the copyright and related rights legislation that applies to your use. For other uses you need to obtain permission from the rights-holder(s) directly, unless additional rights are indicated by a Creative Commons license in the record and/or on the work itself.

This Dissertation has been accepted for inclusion in UNLV Theses, Dissertations, Professional Papers, and Capstones by an authorized administrator of Digital Scholarship@UNLV. For more information, please contact [digitalscholarship@unlv.edu](mailto:digitalscholarship@unlv.edu).

MEASUREMENT OF ANTERIOR TRANSLATION OF THE MANDIBULAR CONDYLE  
USING ULTRASONOGRAPHY

By

Brooke Laskowski

Danielle Hahn

Christensen J. Hardy

A doctoral project submitted in partial fulfillment

of the requirements for the

Doctor of Physical Therapy

Department of Physical Therapy

School of Allied Health Sciences

Division of Health Sciences

The Graduate College

University of Nevada, Las Vegas

May 2017

Copyright by (Brooke Laskowski, Danielle Hahn, Christensen J. Hardy), 2017  
All Rights Reserved



Doctoral Project Approval

The Graduate College The Graduate College

The University Of Nevada, Las Vegas

May x, 2017

This doctoral project prepared by

Brooke Laskowski, Danielle Hahn and Christensen J. Hardy

entitled

Reliability of the Measurement of Anterior Translation of the Mandibular Condyle Using  
Ultrasonography

is approved in partial fulfillment of the requirements for the degree of

Doctor of Physical Therapy

---

*Research Project Coordinator*

---

*Research Project Advisor*

---

*Graduate College Dean*

---

*Chair, Department of Physical Therapy*

## ABSTRACT

**Study Design:** Reliability of clinical measurement

**Objectives:** To establish a standardized ultrasonographic approach to quantify anterior translation of the mandibular condyle during mouth opening by examining the reliability of imaging acquisition and processing.

**Background:** Restricted mouth opening is a common limitation in individuals with temporomandibular dysfunction (TMD), however the arthrokinematics of the temporomandibular joint (TMJ) during mouth opening have not been studied thoroughly. Furthermore, how anterior translation of the mandibular condyle contributes to mouth opening remains unclear.

**Methods:** Twenty-eight subjects without TMD participated. During day 1 of data collection, all subjects performed maximal mouth opening while an examiner placed a linear transducer overlying the TMJ and the zygomatic arch to record dynamic images. On day 2 of data collection, the same procedure was performed on 6 subjects that participated in day 1 of data collection. To establish inter- and intra- rater reliability of imaging processing, 3 examiners measured condylar translations on 2 days with 7 days apart. To determine intra-rater reliability of imaging acquisition, images obtained from 2 days of data collection were analyzed. Intra-class correlation coefficients (ICCs) and standard errors of measurement (SEMs) were used to evaluate reliability. A linear regression model was used to assess the association between anterior condylar translations and mouth opening.

**Results:** Our data revealed excellent ICCs and small SEMs for imaging acquisition and processing. A significant, linear model was found to describe the relationship between condylar anterior translations and mouth opening.

**Conclusions:** Anterior condylar displacement during mouth opening can be measured reliably using ultrasonography.

**Key Words:** temporomandibular joint, anterior translation, mouth opening, reliability

## ACKNOWLEDGEMENTS

This research was made possible by the Graduate & Professional Student Association Grant and the University of Nevada, Las Vegas Physical Therapy Department Grant. The authors would like to thank Kai-Yu Ho, PT for her superior mentoring as principle investigator of this study. The authors would also like to thank Louie Puentedura for his additional help with this project.

## TABLE OF CONTENTS

ABSTRACT .....	iii
ACKNOWLEDGEMENTS .....	v
INTRODUCTION .....	1
METHODS.....	3
RESULTS.....	7
DISCUSSION .....	8
CONCLUSION .....	11
REFERENCES.....	17
CURRICULUM VITAE .....	19



## INTRODUCTION

Restricted mandibular depression (mouth opening) is a common limitation in individuals with temporomandibular dysfunction (TMD),<sup>1</sup> however the arthrokinematics of the temporomandibular joint (TMJ) *in vivo* have been sparsely studied. A common clinical approach to quantify TMJ kinematics of mouth opening is to measure the distance between the tips of upper and lower incisors using a millimeter ruler.<sup>2</sup> Although this method is able to determine if there is an osteokinematic limitation,<sup>2</sup> it fails to give information for determining arthrokinematic abnormalities. Specifically, it has been suggested that anterior translation of the mandibular condyle on the temporal bone is a required arthrokinematic component to achieve mouth opening.<sup>3</sup> To date, current literature reveals conflicting evidence on whether there is an association between mouth opening (osteokinematics) and anterior translation of the mandibular condyle (arthrokinematics).<sup>4,5</sup>

With a 3-dimensional (3D) motion capture system, quantification of the movement of mandibular condyle during mouth opening can be made.<sup>4-6</sup> However, the major challenge of quantifying TMJ kinematics during mouth opening is that the condylar points of interests (located 2 cm subcutaneously) cannot be identified accurately by using skin markers.<sup>6</sup> Baltali and colleagues<sup>6</sup> have reported that computerized tomography is needed in conjunction with a 3D motion capture system to improve the accuracy of reference point locations.

It has been shown that ultrasound imaging allows cost effectiveness, convenience in the clinical setting and no exposure to ionizing radiation.<sup>7</sup> Previous researchers have made attempts to use ultrasound imaging to measure condylar mobility during mouth opening.<sup>8,9</sup> It remains challenging to standardize a reference marker on the mandibular condyle for tracking condylar movements at different frames during mouth opening given that ultrasound imaging reveals only a partial view of the mandibular condyle (a curvilinear, hyperechoic line). Additionally, the association between ultrasonography-measured anterior translation of the mandibular condyle and mouth opening range of motion (ROM) has not yet been studied.

As such, this study aimed to develop a standardized ultrasonographic protocol to measure anterior translation of the mandibular condyle during mouth opening. As measurement errors may result from imaging acquisition (i.e., transducer placement) and data processing (i.e., imaging interpretations) between days, this study was designed to establish reliability for both imaging processing and imaging acquisition. We also aimed to determine the relationship between mouth opening ROM and anterior translation of mandibular condyle.

## METHODS

### Subjects

We recruited 28 participants (14 males and 14 females) between 18 and 45 years of age (average age= 25.9±4.1 years) without a clinical diagnosis of TMD. The sample size was determined based on existing literature with a similar research design for correlating imaging-based measurements with the those quantified by an existing method.<sup>10</sup> Subjects were excluded if they had any of the following: 1) a diagnosis of TMD, 2) pain, swelling, or clicking sound of TMJ, and 3) mouth opening ROM less than 35 mm. Individuals with TMD were excluded to minimize potential bias from existing kinematical abnormalities. We excluded subjects who had mouth opening less than 35 mm as 35 mm is considered a functional range for daily TMJ activities.<sup>11</sup> Prior to participation, all subjects were informed of the nature of the study and signed a consent form approved by the Institutional Review Board of the University of Nevada, Las Vegas.

### Procedures

The study procedure was designed to obtain ultrasound 1) imaging processing reliability and 2) imaging acquisition reliability. Data acquisition was performed on 2 separate days, at least 7 days apart. During day 1 of data collection, imaging was acquired for all 28 subjects for the purposes of obtaining imaging processing reliability among and within examiners. Prior to imaging acquisition, maximum mouth opening ROM was measured using a millimeter ruler on all subjects. On day 2 of data collection, the same ultrasound imaging acquisition procedure was

performed on 6 of the subjects that participated in day 1 of data collection in order to assess the transducer placement reliability (i.e., reliability of imaging acquisition) between days.

### US Imaging Acquisition

A trained investigator obtained ultrasound imaging of bilateral TMJ from all subjects. High-resolution dynamic ultrasound images were acquired at a rate of 25 frames per second using a General Electric NextGen LOGIQe scanner (GE Healthcare, Milwaukee, WI, USA). Brightness-mode ultrasonographic images were captured using a linear transducer at a central frequency of 10 MHz and depth of 3 cm. Subjects were asked to repeatedly open the mouth as wide and as gently as possible while seated. The transducer was placed transversely overlying the TMJ and the zygomatic arch to ensure that the lateral edge of the mandibular condyle remained visible (FIGURE 1).<sup>12</sup> When the mandibular condyle was consistently visible at both closed and mouth opening positions, a 10-second video was recorded. A total of three 10-second videos were collected on each side of the subjects.

### Mouth Opening ROM Measurement

Subjects were asked to perform maximal mouth opening in a seated position 3 separate times. A single investigator recorded the distance between the tips of upper and lower incisors (FIGURE 2).<sup>2</sup> The greatest range achieved out of 3 attempts was recorded to represent the subject's mouth opening ROM. To obtain the test-retest reliability, one investigator performed repeated measurement of 10 subjects on each day with 7 days apart. Intra-class correlation coefficients

(ICCs) and standard errors of measurement (SEM) were used to assess the reliability of the investigator between day 1 and 2. The investigator demonstrated excellent measurement reliability (ICC = 0.958) with a low SEM (0.764 mm).

## Data Processing

### US Data Processing

ImageJ software (National Institutes of Health, Bethesda, MD, USA) was used to quantify anterior translation of mandibular condyle during mouth opening. Anterior translational distance was defined as the traveling distance of the mandibular condyle from the mouth closed position to the mouth opening position. Specifically, using the still image frames of both closed and opening, an oval with the same size and radius was drawn around the lateral aspect of mandibular condyle to represent the mandibular condyle in each position (FIGURE 3 A&B). An oval was chosen because of the ovoid nature of the mandibular condyle.<sup>13</sup> A line was then measured from the center of each oval to represent the distance that the condyle translated from closed to opening positions (FIGURE 3).

To establish inter-and intra- rater reliability of imaging processing, 3 investigators measured condylar translational distance during mouth opening of 28 subjects on 2 separate days with 7 days apart. A single investigator performed the measurement on the images of the 6 participants who underwent both days 1 and 2 of data collection for the purposes of obtaining imaging acquisition reliability. Each set of images (right and left) of the subjects was measured 3 times and the average values of each side were used for statistical analyses.

## Statistical Analyses

ICCs and SEMs were used to determine reliability of imaging processing and acquisition. The proposed US imaging method was deemed acceptable if the ICCs were greater than 0.9 (excellent).<sup>14</sup> A linear regression analysis was used to determine the relationship between anterior condylar translation and maximum mouth opening ROM. Averages of right and left anterior translation distances measured by all 3 investigators were used to obtain the anterior translation values used in the regression analysis. All statistical analyses were performed on SPSS ® 22.0 (International Business Machines Corp. New York, USA). Statistical significance was defined as a p-value of <0.05.

## RESULTS

Analysis of the data revealed excellent inter-rater reliability and low SEMs among the 3 examiners for measurement of the right and left TMJs (ICCs = 0.989 - 0.999; SEM = 0.370-0.471 mm) (TABLE 1). Excellent intra-rater reliability for measurement of both TMJs was also achieved (ICCs = 0.960-0.977; SEMs = 0.704- 0.871 mm) (TABLE 1). Our data also revealed excellent intra-rater reliability for ultrasound imaging acquisition of the right and left TMJs (ICC = 0.929-0.939; SEM = 0.901-1.199 mm) (TABLE 1). The regression analysis revealed a linear model to describe the relationship between condylar anterior translation and mouth opening ROM with a significant correlation coefficient of 0.673 ( $y=0.924x + 41.153$ ;  $p<0.0001$ ) (FIGURE 4).

## DISCUSSION

The primary purpose of the current study was to develop a standardized ultrasonographic protocol for measuring anterior translation of the mandibular condyle during mouth opening. Our findings demonstrated excellent reliability in imaging acquisition and processing, suggesting that the ultrasound protocol established in this study is robust, non-variable and can be clinically applied. This is the first study to evaluate the relationship between ultrasonography-measured anterior condylar translation and mouth opening. Our findings revealed a linear regression model describing the association between mouth opening ROM and anterior translation of mandibular condyle during mouth opening.

Our findings showed that ROM during mouth opening ranged from 40 to 62 mm (mean = 52.75  $\pm$  1.09 mm) and condylar translation from 4.03 to 20.51 mm (mean = 12.55  $\pm$  2.4 mm) (Figure 4). The kinematics of mouth opening measured in the current study are comparable with those reported in existing literature.<sup>4,5,9</sup> Through use of a 3D tracking system, Travers et al.<sup>5</sup> showed that the average maximal mouth opening was 46.6 mm and the average anterior condylar translation was 11.9 mm in individuals without TMD. Similarly, Salaorni and colleagues<sup>4</sup> reported ROM during mouth opening ranging from 43 to 72 mm (mean = 55  $\pm$  6 mm) and condylar translation ranging from 5 to 25 mm (mean = 14  $\pm$  4.2 mm) in individuals without TMD. Using ultrasonography, Chen et al.<sup>9</sup> reported an average translational distance of 10.3  $\pm$  3.7 mm during mouth opening in subjects with no TMD.



The current literature reveals conflicting evidence regarding the association between anterior condylar translation and mouth opening ROM. Travers and the colleagues<sup>5</sup> reported that no significant correlation existed between mouth opening ROM and condylar translation. Our data agreed with the findings reported by Salaorni et al.<sup>4</sup> who showed a linear relationship between condylar translation and opening angle ( $R=0.993$ ) using an optoelectric tracking system. These inconsistent findings between our study and their reports may be due to different methodology being used between studies. For instance, the non-significant findings reported by Travers et al. may have been caused by the inaccurate placements and/or movements of skin markers during mouth opening. As the mandibular condyle cannot be visualized directly, Saloni et al.<sup>4</sup> utilized a mathematical model to estimate the movement of a preselected condylar point and determine the distance of condylar movement during mouth opening, thereby yielding a higher coefficient. Our ultrasound imaging protocol employed a more direct approach through visual identification of the true anatomical condylar head. We believe that such direct identifications are more representative of actual condylar location than mathematical estimation, since osseous components of the TMJ vary significantly between individuals.<sup>13</sup> The ultrasound imaging protocol herein accounts for this variation and decreases confounding effects of osseous condylar variation between subjects.

With respect to the findings of the current study, 2 major limitations should be recognized. First, only the reliability of ultrasound imaging acquisition and processing of anterior condylar translation was assessed. Future studies should assess the validity of the ultrasound imaging protocol established here through comparison with advanced imaging methods to measure

anterior condylar translation, such as magnetic resonance imaging or computerized tomography. Furthermore, future studies should examine the reliability of the ultrasound imaging protocol established here amongst persons with TMD since TMJ kinematics of healthy subjects may differ from those with TMD.

## CONCLUSION

Our data demonstrated that anterior condylar displacement during mouth opening can be measured reliably using our ultrasound imaging approach. A linear regression model was also established to describe the relationship between anterior condylar translation and mouth opening. These findings can impact the evaluation and treatment for individuals with TMD.

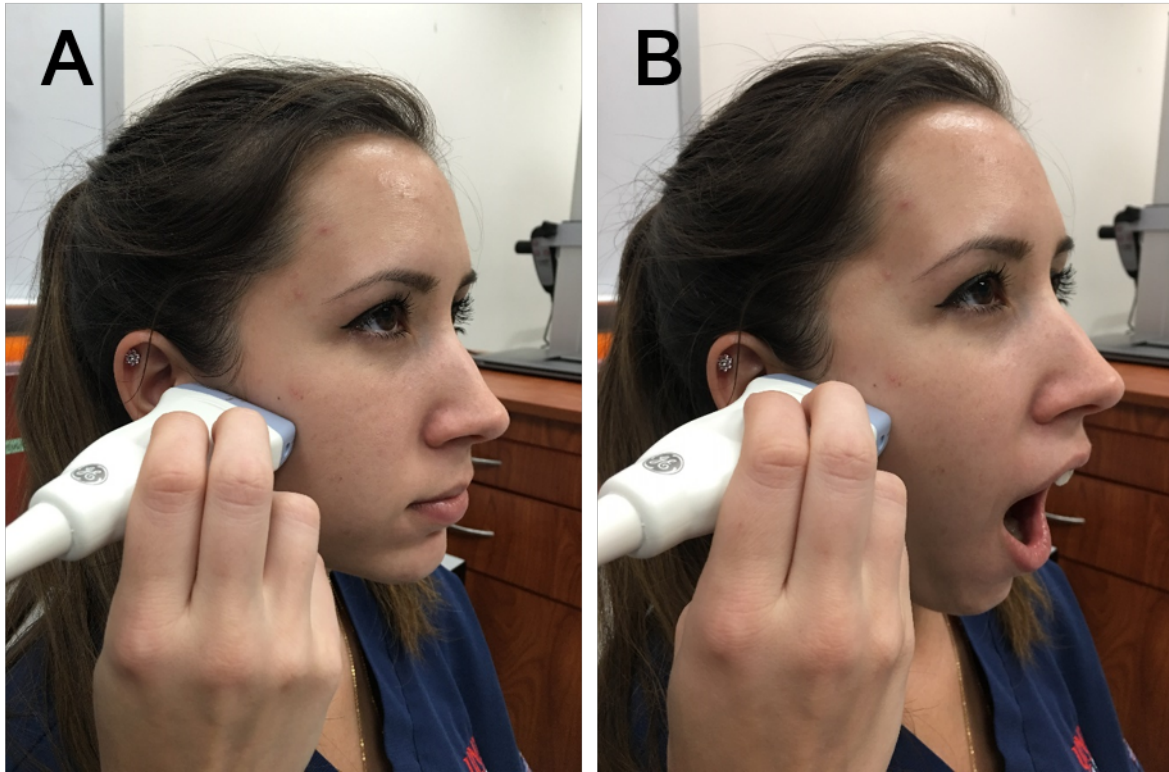


FIGURE 1. Ultrasound transducer placement at (A) mouth closed and (B) mouth opening positions.

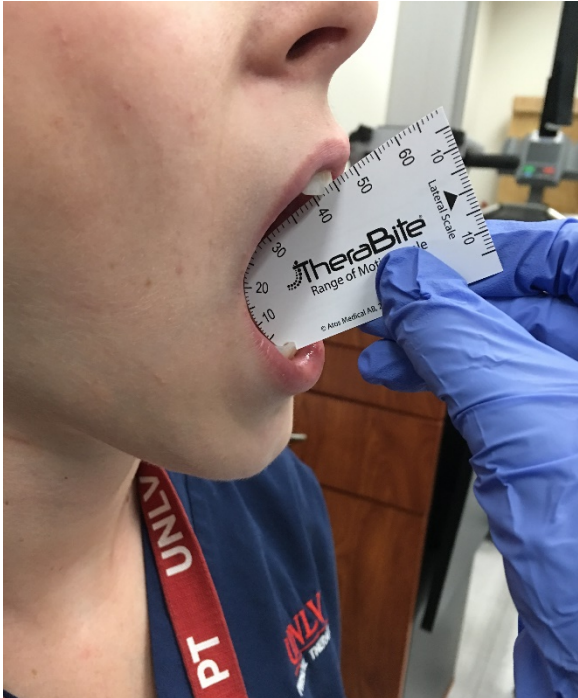


FIGURE 2. Measurement of mouth opening range of motion using a millimeter ruler.

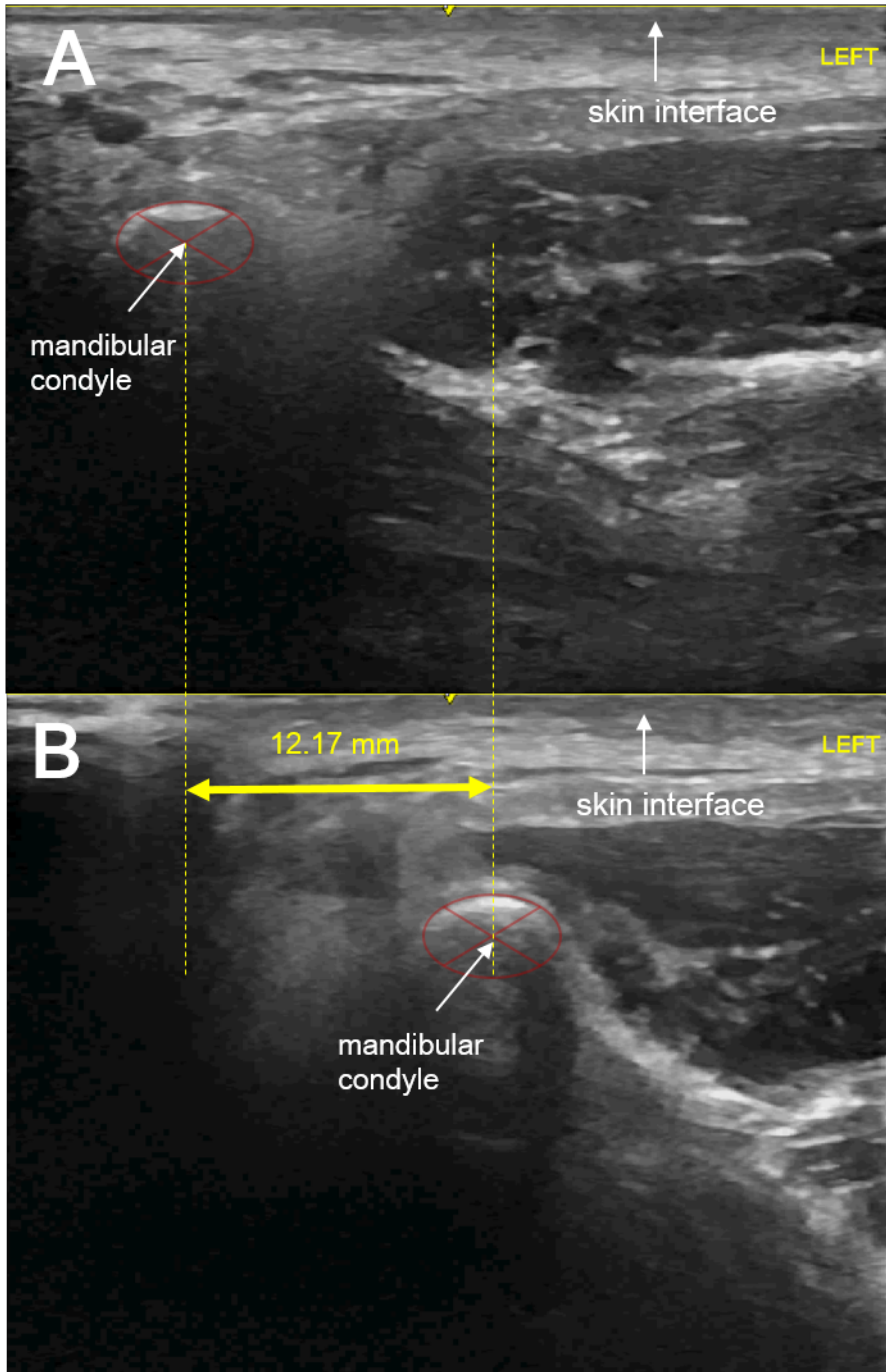


FIGURE 3. The transverse section of ultrasound imaging of left TMJ at (A) mouth closed and (B) mouth opening positions. Each oval represents the lateral aspect of the mandibular condyle. The anterior displacement distance was defined as the distance between the centers of the ovals at the 2 positions.

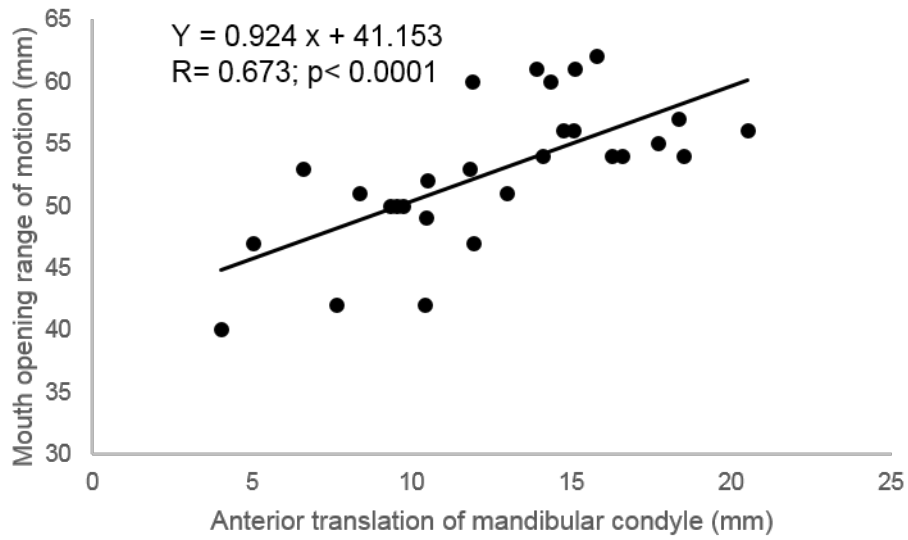


FIGURE 4. The linear regression model for describing the association between anterior translation of the mandibular condyle and mouth opening range of motion.

TABLE 1. Summary of the reliability of imaging processing and imaging acquisition. Abbreviations: ICC = intra-class correlation coefficient; SEM= standard error of measurement.

<b>Imaging Processing</b>													<b>Imaging Acquisition</b>	
<b>Intra-rater</b>						<b>Interrater</b>						<b>Intra-rater</b>		
	<b>Examiner 1</b>		<b>Examiner 2</b>		<b>Examiner 3</b>		<b>Examiner 1 vs. 2</b>		<b>Examiner 1 vs. 3</b>		<b>Examiner 2 vs. 3</b>		<b>Examiner 1</b>	
	ICC	SEM (mm)	ICC	SEM (mm)	ICC	SEM (mm)	ICC	SEM (mm)	ICC	SEM (mm)	ICC	SEM (mm)	ICC	SEM (mm)
<b>Right</b>	0.975	0.731	0.970	0.793	0.977	0.704	0.994	0.371	0.999	0.144	0.994	0.370	0.939	1.199
<b>Left</b>	0.968	0.737	0.960	0.871	0.971	0.717	0.989	0.471	0.999	0.136	0.990	0.451	0.929	0.901



## REFERENCES

1. Kundu H, Basavaraj P, Kote S, Singla A, Singh S. Assessment of TMJ Disorders Using Ultrasonography as a Diagnostic Tool: A Review. *Journal of clinical and diagnostic research : JCDR* 2013;7:3116-20.
2. Walker N, Bohannon RW, Cameron D. Discriminant validity of temporomandibular joint range of motion measurements obtained with a ruler. *J Orthop Sports Phys Ther* 2000;30:484-92.
3. Neumann DA. *Kinesiology of the musculoskeletal system : foundations for rehabilitation*. 2nd ed. St. Louis, Mo.: Mosby/Elsevier; 2010.
4. Salaorni C, Palla S. Condylar rotation and anterior translation in healthy human temporomandibular joints. *Schweiz Monatsschr Zahnmed* 1994;104:415-22.
5. Travers KH, Buschang PH, Hayasaki H, Throckmorton GS. Associations between incisor and mandibular condylar movements during maximum mouth opening in humans. *Arch Oral Biol* 2000;45:267-75.
6. Baltali E, Zhao KD, Koff MF, Keller EE, An KN. Accuracy and precision of a method to study kinematics of the temporomandibular joint: combination of motion data and CT imaging. *J Biomech* 2008;41:2581-4.
7. Finnoff JT, Hall MM, Adams E, et al. American Medical Society for Sports Medicine (AMSSM) position statement: interventional musculoskeletal ultrasound in sports medicine. *PM & R : the journal of injury, function, and rehabilitation* 2015;7:151-68 e12.
8. Braun S, Hicken JS. Ultrasound imaging of condylar motion: a preliminary report. *Angle Orthod* 2000;70:383-6.

9. Chen HY, Wu SK, Lu CC, You JY, Lai CL. Assessing the mobility of the mandibular condyle by sonography. *Patient Prefer Adherence* 2014;8:1419-25.
10. Kulig K, Harper-Hanigan K, Souza RB, Powers CM. Measurement of femoral torsion by ultrasound and magnetic resonance imaging: concurrent validity. *Phys Ther* 2010;90:1641-8.
11. Dimitroulis G, Dolwick MF, Gremillion HA. Temporomandibular disorders. 1. Clinical evaluation. *Aust Dent J* 1995;40:301-5.
12. Ho KY, Ho S, Colletti PM. Use of Ultrasonography for Assessing Treatment Efficacy in a Case With Ankylosis of the Temporomandibular Joint. *J Orthop Sports Phys Ther* 2016;46:225.
13. Hegde S, BN P, Shetty SR. Morphological and Radiological Variations of Mandibular Condyles in Health and Diseases: A Systematic Review. *Dentistry* 2013;3:154.
14. Cicchetti DV. Guidelines, Criteria, and Rules of Thumb for Evaluating Normed and Standardized Assessment Instruments in Psychology. *Psychological Assessment* 1994;6:284-90.

## CURRICULUM VITAE

Brooke Laskowski, SPT  
124 Lawndale Lane Sneads Ferry, NC 28460  
(602) 550-4412  
brookebasar@gmail.com

### **Objective**

I seek to continually support and improve the profession of physical therapy by continually enhancing my education, using evidenced-based practice, and assisting the well-being of my community with the skills I have attained.

### **Education**

**Bachelors of Science in Exercise Science** **2010-2013**  
Northern Arizona University (NAU) Flagstaff, AZ

**Candidate for Doctorate of Physical Therapy GPA: 3.79/4.0** **2014-Current**  
University of Nevada, Las Vegas (UNLV) Las Vegas, NV  
Graduation date: Spring 2017

### **Graduation Research Project**

Research Advisor- Dr. Kai-Yu Ho, MSPT, Ph.D

The primary purpose of this study was to investigate the reliability of using ultrasound (US) imaging for measuring TMJ arthrokinematics (i.e., anterior translation of the mandibular condyle) during mouth opening. The secondary purpose was to determine the relationship between osteokinematics (i.e., global joint range) and arthrokinematics during maximal mouth opening.

### **Peer Reviewed Scientific and Professional Presentations** **02/2017**

Hahn, D., Hardy, C., Laskowski, B., Puentedura, L., Ho, KY. Reliability of the Measurement of Anterior Translation of the Mandibular Condyle Using Ultrasonography. 2017 APTA Combined Sections Meeting. San Antonio, TX, USA. February 16-18, 2017. (submitted)

### **Professional Experience**

**Summerlin Hospital Las Vegas, NV** **07-09/2016**  
Student physical therapist

- Inpatient and outpatient pediatric rotation

**Naval Medical Center San Diego, San Diego, CA** **10-12/2016**

Student physical therapist

- Outpatient orthopedic rotation

**Premier Nursing and Rehab Center, Jacksonville, NC** **01-03/2017**  
• Skilled nursing facility rotation

**Spooner Physical Therapy, Phoenix, AZ** **06-08/2015**  
Student physical therapist  
• Outpatient orthopedic clinical rotation

**Center for Athletic Performance and Physical Therapy** **05/2013-08/2014**  
**Cave Creek, AZ**

Physical Therapy Technician  
• Assist patients through exercise programs, ensure cleanliness and safety of clinic and equipment, and coordinate with other staff members to ensure time management and ease of care.

**Professional Development**

Combined Sections Meeting of the American Physical Therapy Association **02/2017**

Combined Sections Meeting of the American Physical Therapy Association **02/2015**

Danielle Hahn, SPT  
10421 Fuji Ct Las Vegas, NV 89129  
(702) 249-0489  
hahnd2@unlv.nevada.edu

## Objective

I believe the profession of physical therapy is strengthened through well-educated practitioners who utilize evidenced-based practice to guide their physical therapy endeavors. My current education and achievements reflect this belief and I hope to continue on this path for the duration of my physical therapy career.

## Education

### Bachelors of Science in Health and Exercise Science

Oral Roberts University (ORU) Tulsa, OK

**GPA: 3.86**

### Candidate for Doctorate of Physical Therapy

University of Nevada, Las Vegas (UNLV) Las Vegas, NV

**GPA: 3.73**

Graduation date: Spring 2017

## Graduate Research Project

Research Advisor - Dr. Kai-Yu Ho, MSPT, Ph.D.

The primary purpose of this study was to investigate the reliability of using ultrasound (US) imaging for measuring TMJ arthrokinematics (i.e., anterior translation of the mandibular condyle) during mouth opening.

## Continuing Education

- 2016 Combined Sections Meeting of the American Physical Therapy Association
- 2017 Combined Sections Meeting of the American Physical Therapy Association
- AHA Certified BLS for Healthcare Provider (CPR and AED) – 2011 to present

## Professional Experience

### Cleveland Clinic – Lou Ruvo Center

#### For Brain Health

Las Vegas, NV

1/09-3/31/2017

Student Physical Therapist

- Outpatient neurological clinical rotation

### Summerlin Hospital

Las Vegas, NV

10/10-12/21/2016

Student Physical Therapist

- Inpatient rehabilitation clinical rotation

### Veterans Association Hospital

Phoenix, AZ

7/18-9/30/2016

Student Physical Therapist

- Inpatient acute care clinical rotation

**University of Las Vegas, Nevada**                      **Las Vegas, NV**                      **8/18/2015-5/16/2016**  
 Graduate Assistant

- Assist Catherine Turner, DPT, OCS. with class organization, laboratory set-up and cleanup, as well as conducting open labs for first year students for various classes.

**Select Physical Therapy**                      **Scottsdale, AZ**                      **06/29-8/7/2015**

Student Physical Therapist

- Outpatient orthopedic clinical rotation.

**Refereed Articles**

- Laskowski B, **Hahn D**, Hardy C, Puentedura E, Ho KY. *Measurement of anterior translation of the mandibular condyle using ultrasonography*. Submitted to Journal of Orthopaedic and Sports Physical Therapy. 3/17

**Peer Reviewed Scientific and Professional Presentations**

- Laskowski B, **Hahn D**, Hardy C, Puentedura E, Ho KY. *Measurement of anterior translation of the mandibular condyle using ultrasonography*. 2017 APTA Combined Sections Meeting, San Antonio, TX USA (Orthopaedic poster presentation award nominee)

Christensen J. Hardy, MS, SPT  
933 Scarlet Haze Avenue, Las Vegas, NV 89183-6331  
(702) 371-6231  
javierc2@unlv.nevada.edu

**Objective:**

My exposure to an educational foundation based on research, evidence and clinical experience has shaped my outlook towards a comprehensive future of Physical Therapy. I strive to propagate these fundamentals by implementing them in my interactions with patients, students and colleagues.

**Education:**

**Bachelor of Science in Biology**

University of Nevada, Las Vegas

**Master of Science in Biology, Concentration: Integrative Physiology**

University of Nevada, Las Vegas

Clinical Instructor – Dr. Carl Reiber, Ph.D.

Thesis: *The Grass Shrimp, Palaemonetes pugio: Hypoxic Influences on Embryonic Development*

**Doctorate of Physical Therapy Candidate**

University of Nevada, Las Vegas

Research Advisor - Dr. Kai-Yu Ho, MSPT, Ph.D.

The primary purpose of this study was to investigate the reliability of using ultrasound (US) imaging for measuring TMJ arthrokinematics (i.e., anterior translation of the mandibular condyle) during mouth opening.

**Continuing Education:**

- 2016 Combined Sections Meeting of the American Physical Therapy Association
- 2017 Combined Sections Meeting of the American Physical Therapy Association
- ECG for Physical Therapists Course – 9/2015
- AHA Certified BLS for Healthcare Provider (CPR and AED) – 2014 to present

**Professional Experience:**

**HealthSouth Rehabilitation Clinic**                      **Las Vegas, NV**                      **1/09-3/31/2017**  
Student Physical Therapist

- Inpatient rehabilitation clinical rotation

**Spring Valley Hospital**                                      **Las Vegas, NV**                                      **10/10-12/21/2016**

Student Physical Therapist

- Inpatient acute orthopedic and NICU clinical rotation

**Select Physical Therapy**                                      **North Las Vegas, NV**                                      **7/18-9/30/2016**

Student Physical Therapist

- Outpatient orthopedic clinical rotation

**FYZICAL Therapy & Balance**                                      **Las Vegas, NV**                                      **6/29-8/7/2015**

Student Physical Therapist

- Outpatient neurological clinical rotation

**University of Nevada, Las Vegas**                                      **Las Vegas, NV**                                      **2011**

Guest Lecturer

- School of Allied Health Sciences
- “Human Anatomy & Physiology II: Blood and Immunology”

**University of Nevada, Las Vegas**                                      **Las Vegas, NV**                                      **2010 – 2014**

Part-Time Instructor and Graduate Assistant

- Human Anatomy & Physiology Laboratory

### **Professional Memberships:**

- American Physical Therapy Association
- Nevada Physical Therapy Association Student Special Interest Group
- National Society of Leadership and Success
- Phi Kappa Phi Honor Society

### **Refereed Articles:**

- Laskowski B, Hahn D, **Hardy CJ**, Puentedura E, Ho KY. *Measurement of anterior translation of the mandibular condyle using ultrasonography*. Submitted to Journal of Orthopaedic and Sports Physical Therapy. 3/17
- **Javier, Christensen C.**, "The Grass Shrimp, Palaemonetes, Pugio: Hypoxic Influences on Embryonic Development" (2014). *UNLV Theses, Dissertations, Professional Papers, and Capstones*. 2015.

### **Peer Reviewed Scientific and Professional Presentations:**

- Laskowski B, Hahn D, **Hardy CJ**, Puentedura E, Ho KY. *Measurement of anterior translation of the mandibular condyle using ultrasonography*. *2017 APTA Combined Sections Meeting*, San Antonio, TX USA (Orthopaedic poster presentation award nominee)